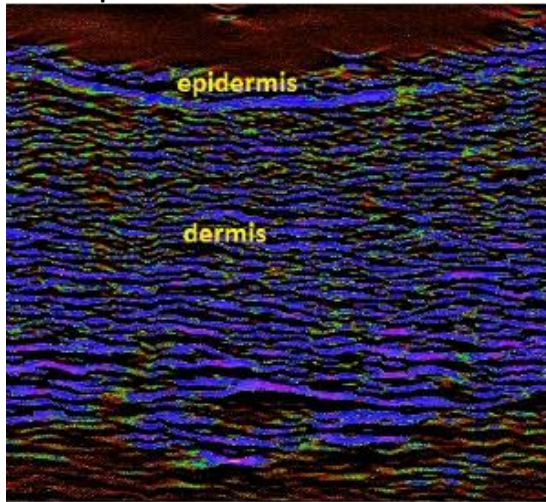


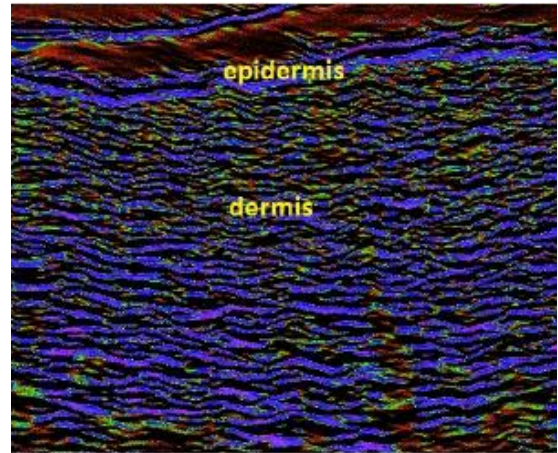
Results – HW

Figure 10. Scans comparing time 0 scans against 4 weeks for each skin location.

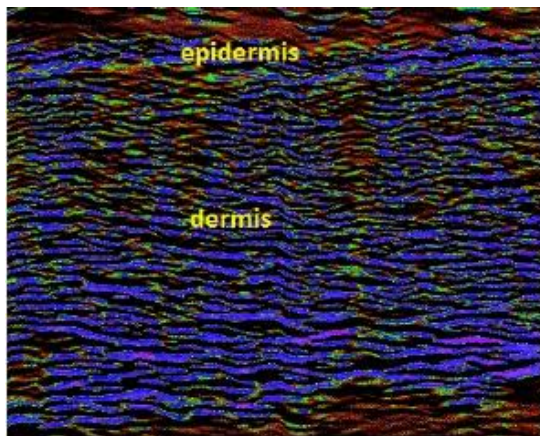
Left Scapula - Time 0



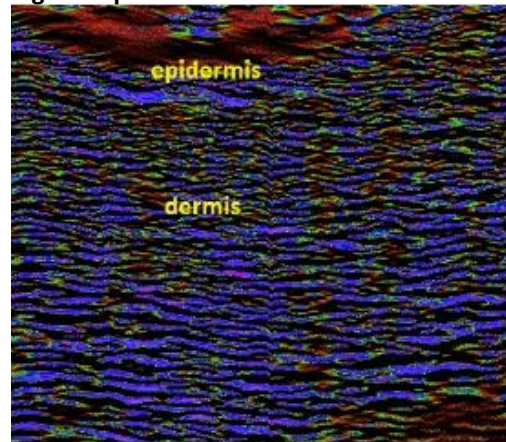
Left Scapula – 4 Weeks



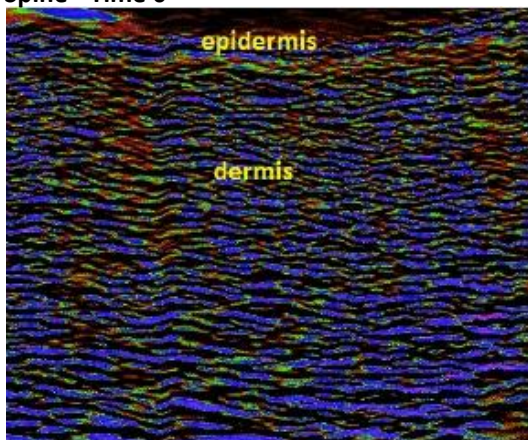
Right Scapula - Time 0



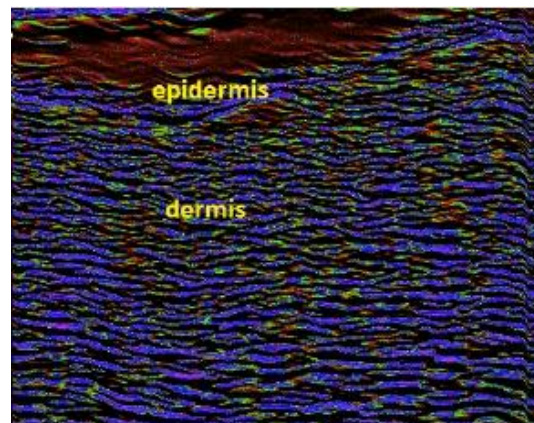
Right Scapula – 4 Weeks



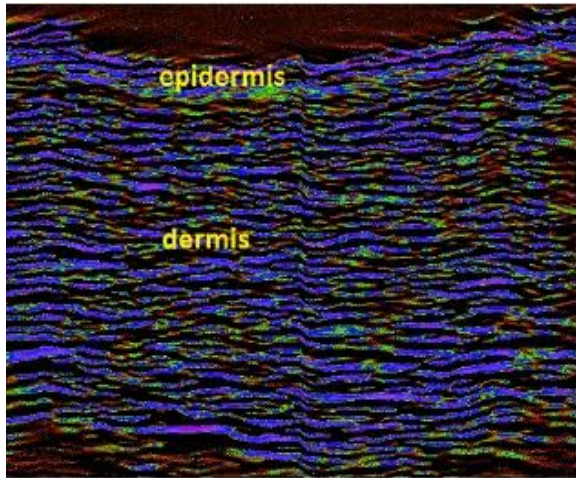
Spine - Time 0



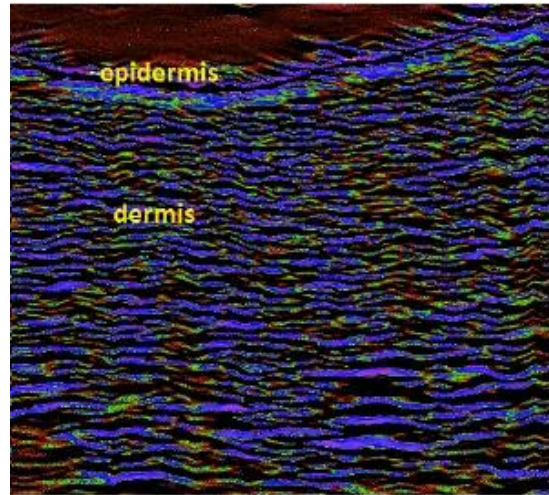
Spine – 4 Weeks



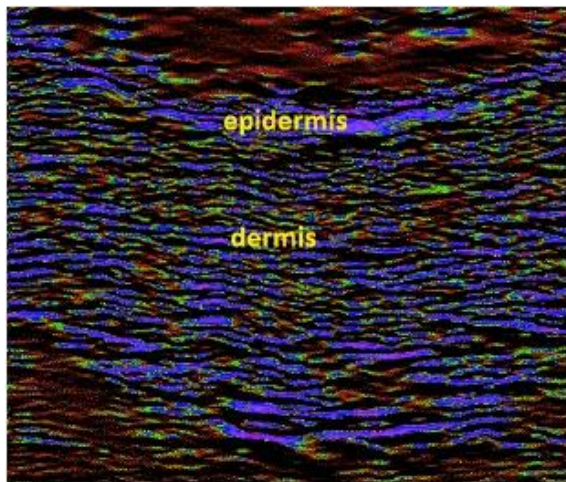
Sacrum - Time 0



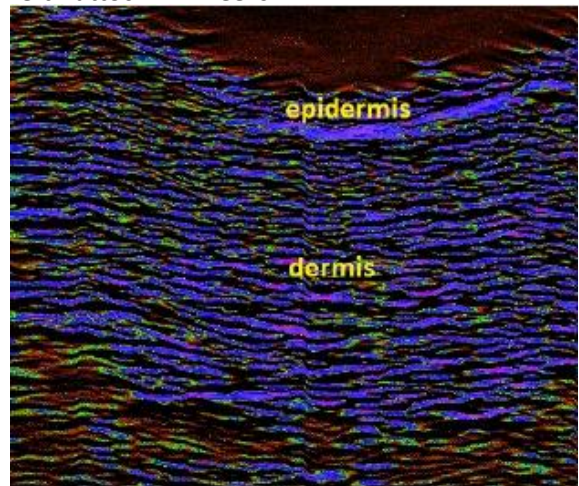
Sacrum - 4 Weeks



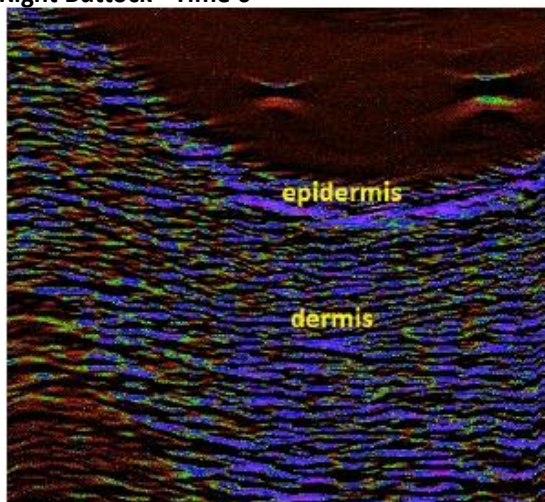
Left Buttock - Time 0



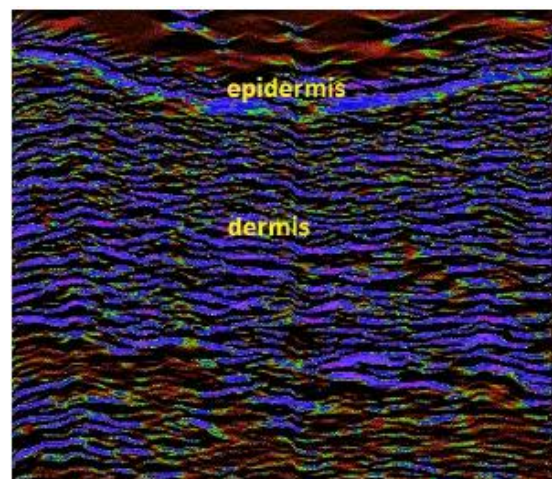
Left Buttock - 4 Weeks



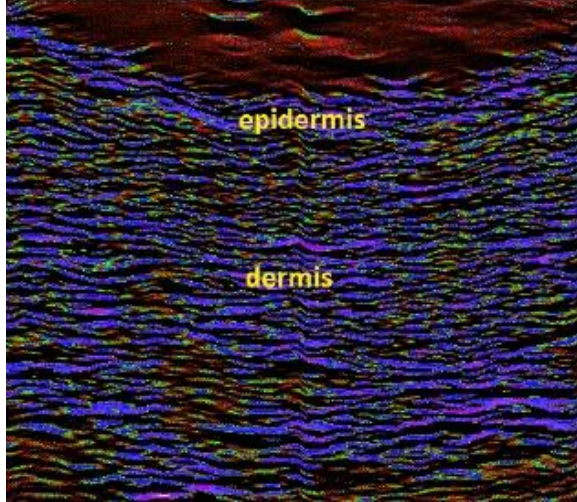
Right Buttock - Time 0



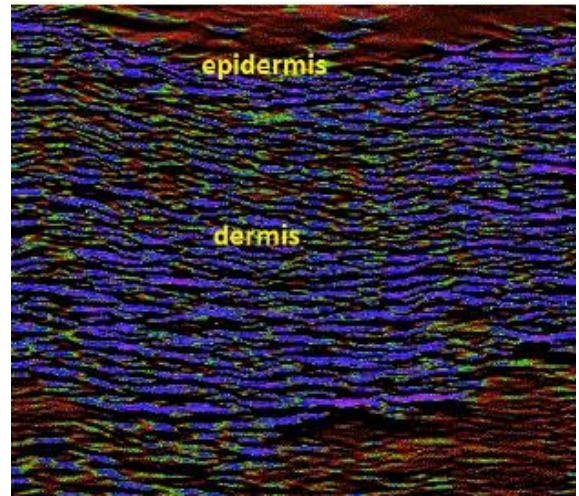
Right Buttock - 4 Weeks



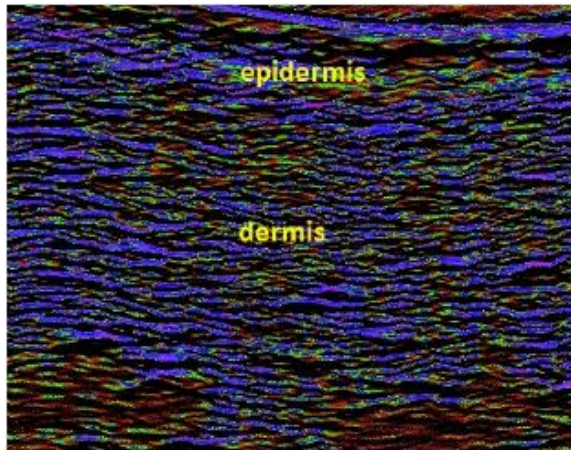
Left Hip - Time 0



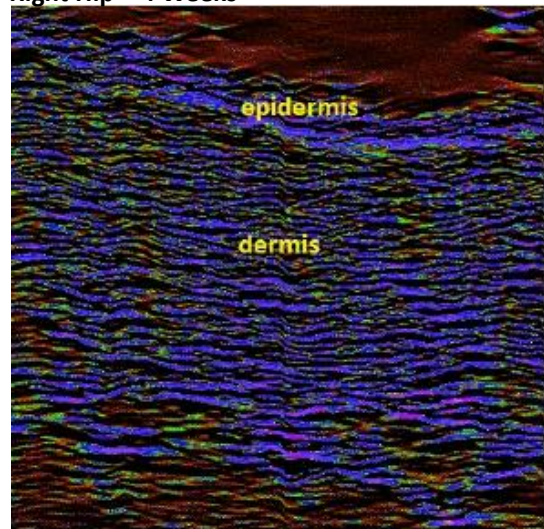
Left Hip - 4 Weeks



Right Hip - Time 0

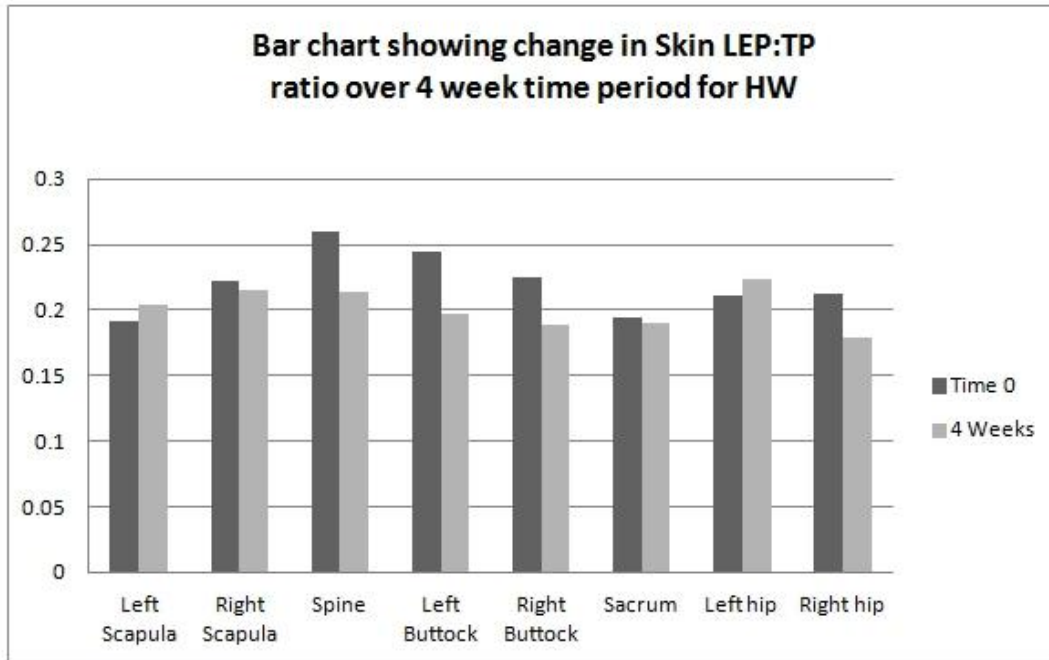


Right Hip - 4 Weeks



The scans generally indicate that the skin in all areas has not changed greatly over the 4 weeks. Analysis of all the scans for this subject is shown in figure 11.

Figure 11 Graph of LEP: TP ratio for HW Skin Analysis

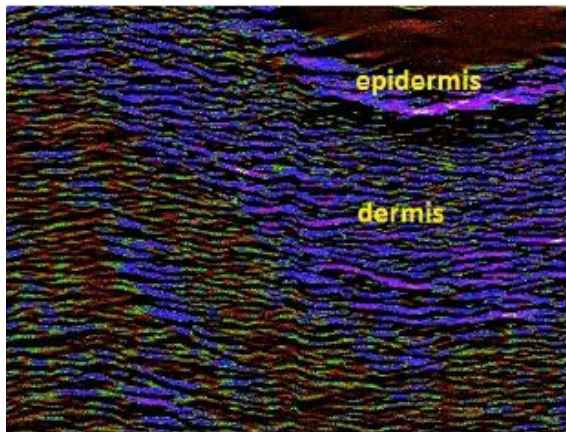


The results show that there were some changes to be seen in the oedema levels in the skin of this subject when comparing time 0 with 4 weeks. The spine, left and right buttock and right hip showed a decrease in oedema. No significant changes were seen in other areas.

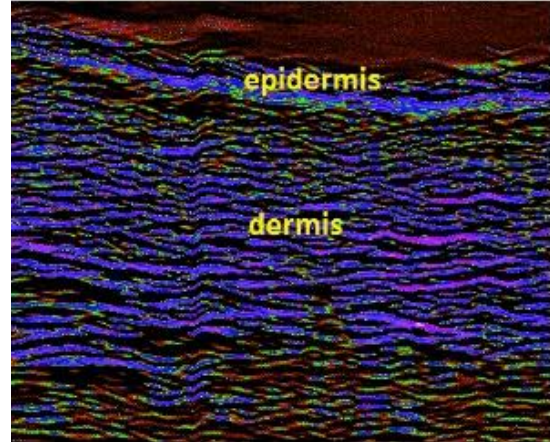
Results – JB

Figure 12. Scans comparing time 0 scans against 4 weeks for each skin location.

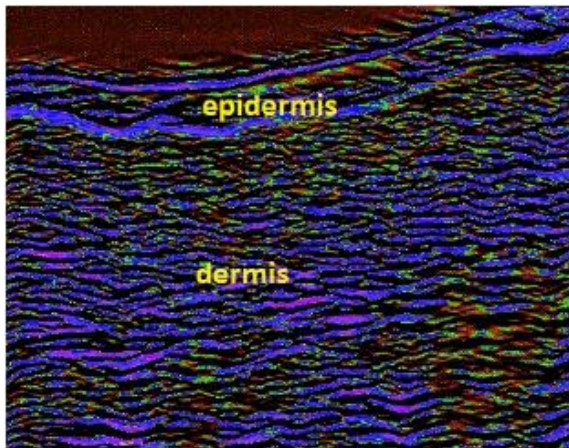
Left Scapula - Time 0




Left Scapula – 4 Weeks



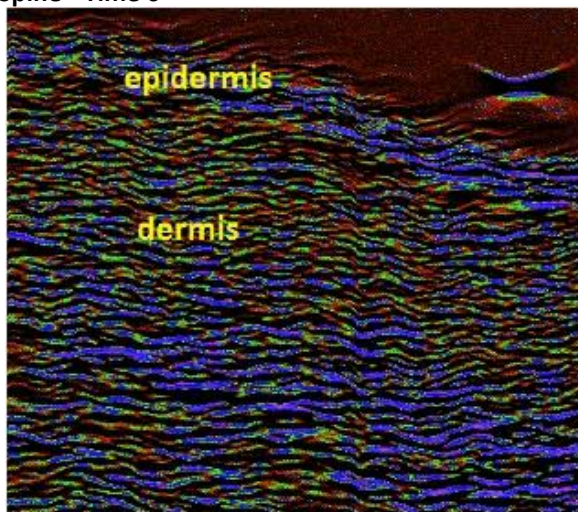
Right Scapula - Time 0



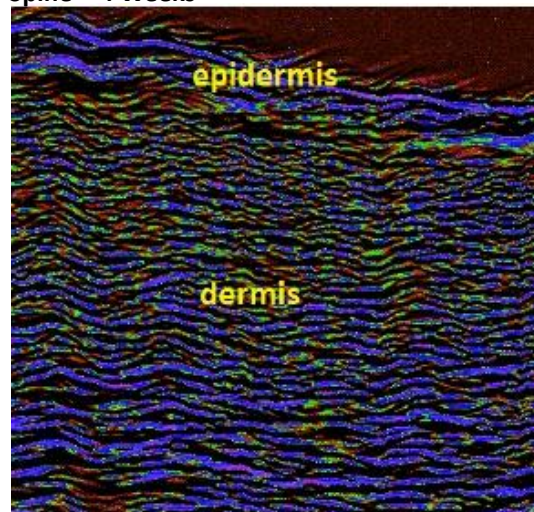
Right Scapula – 4 Weeks



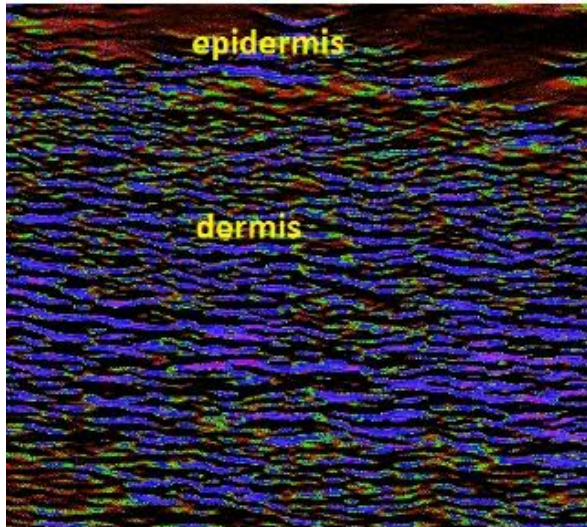
Spine - Time 0



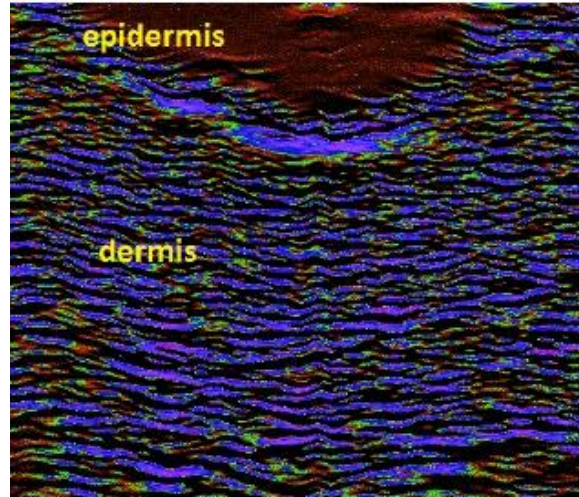
Spine – 4 Weeks



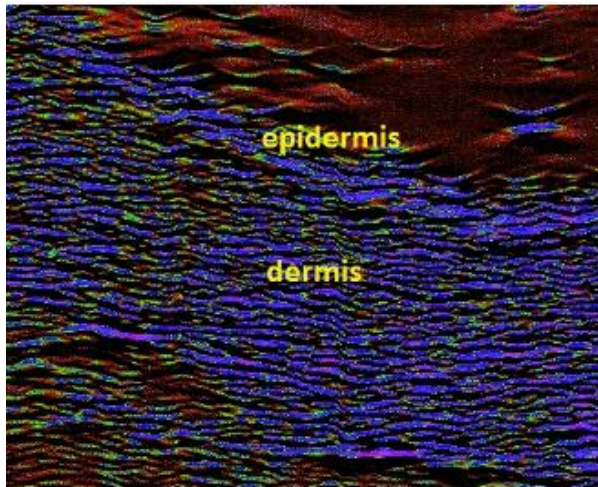
Sacrum - Time 0



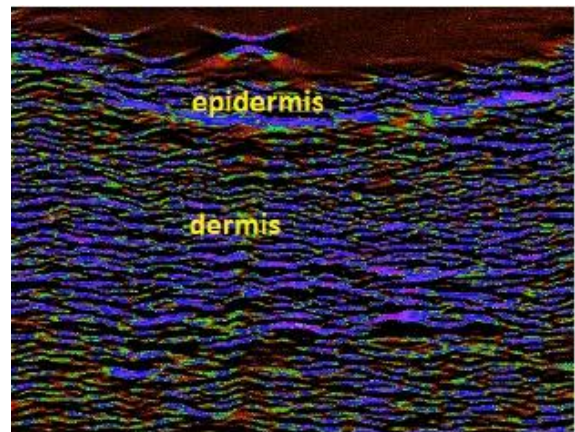
Sacrum - 4 Weeks



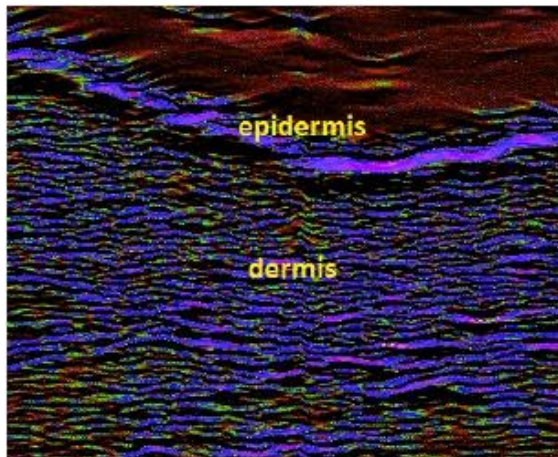
Left Buttock - Time 0



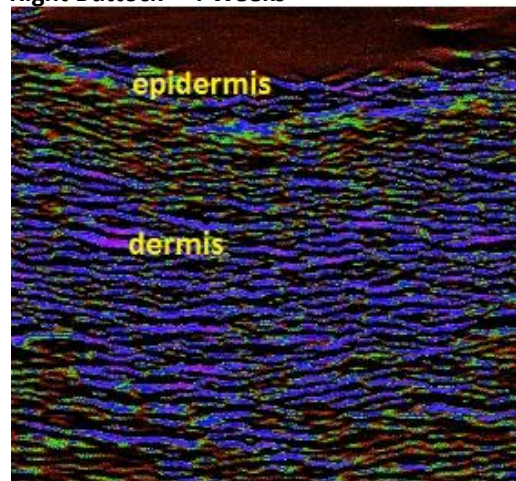
Left Buttock - 4 Weeks



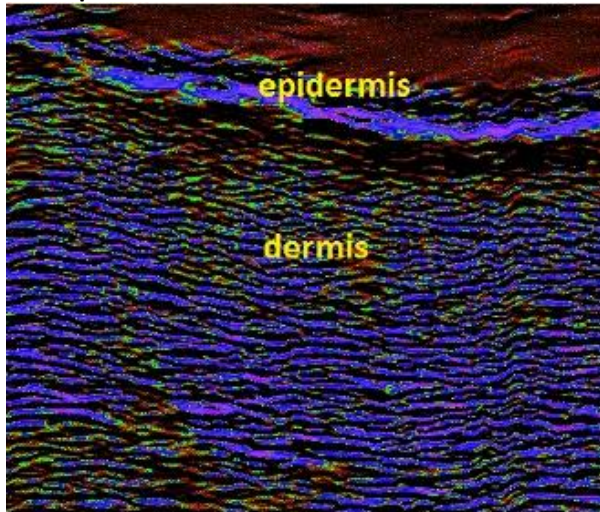
Right Buttock - Time 0



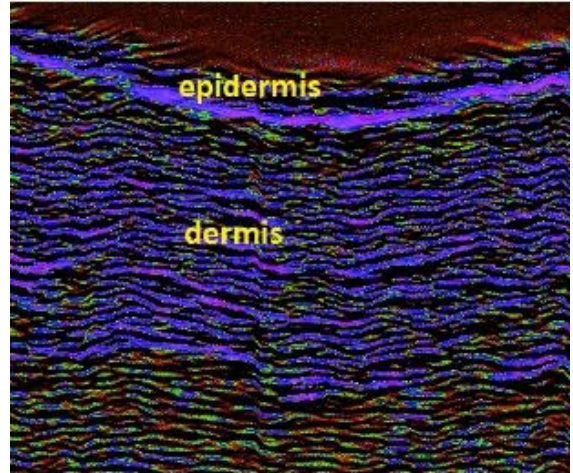
Right Buttock - 4 Weeks



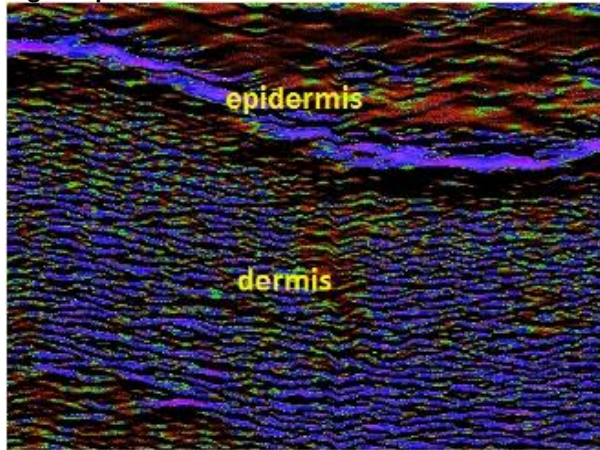
Left Hip - Time 0



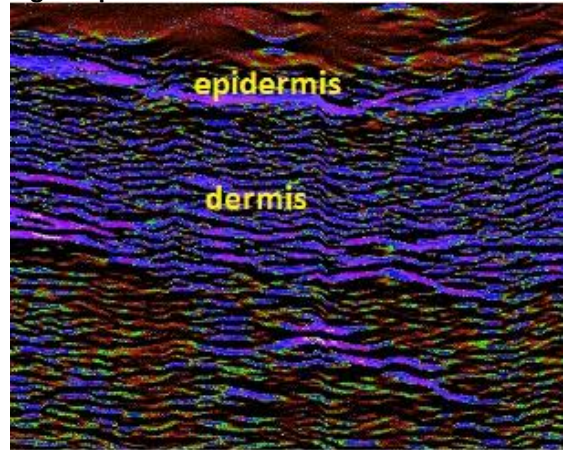
Left Hip - 4 Weeks



Right Hip - Time 0

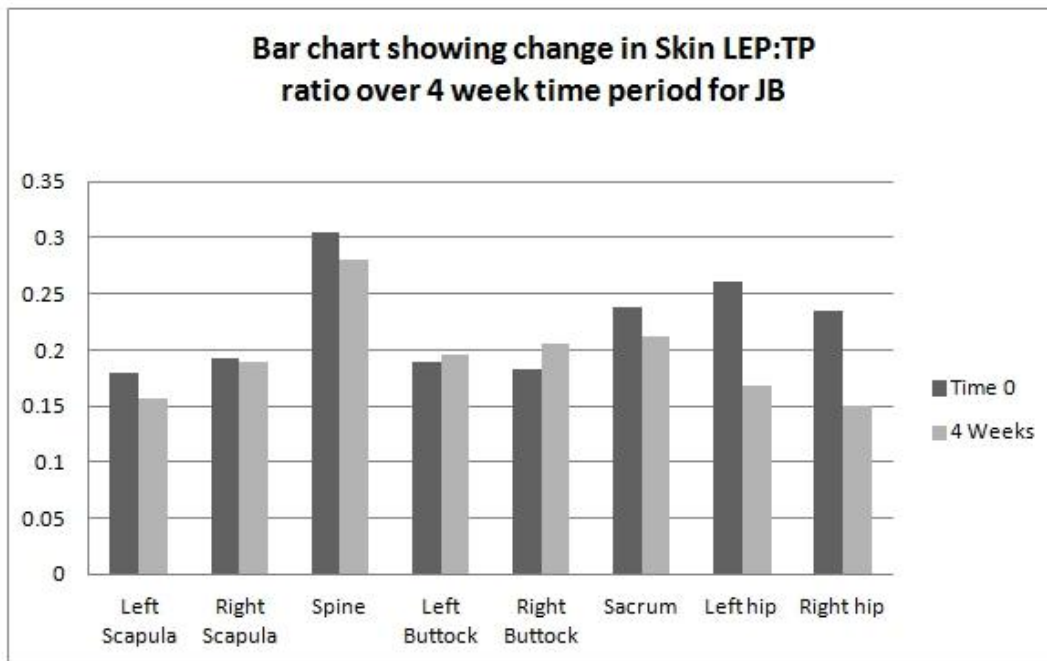


Right Hip - 4 Weeks



The scans indicate a mixture of results, some areas have improved and others have gained more oedema over the 4 weeks. Analysis of all the scans for this subject is shown in figure 13.

Figure 13 Graph of LEP: TP ratio for JB Skin Analysis

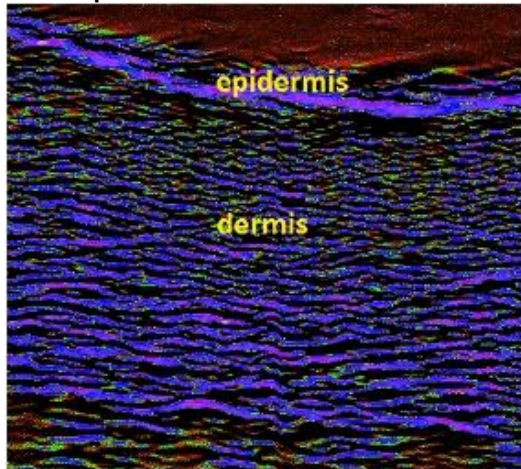


The results show that there are changes to be seen in the oedema levels in the skin of this subject when comparing time 0 with 4 weeks. No significant change seen in right scapula and left buttock. There was a slight increase in oedema seen in the right buttock. The left scapula, spine, sacrum, left and right hips showed a decrease in oedema.

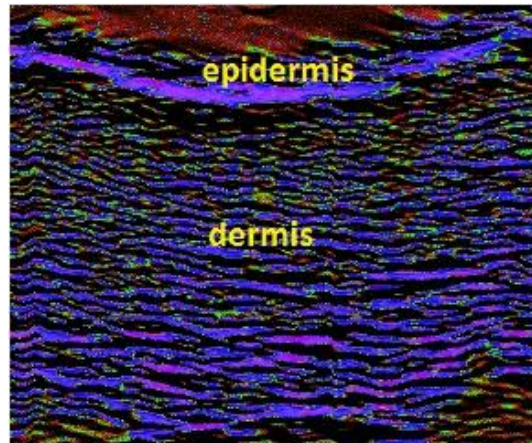
Results – JM

Figure 14. Scans comparing time 0 scans against 4 weeks for each skin location.

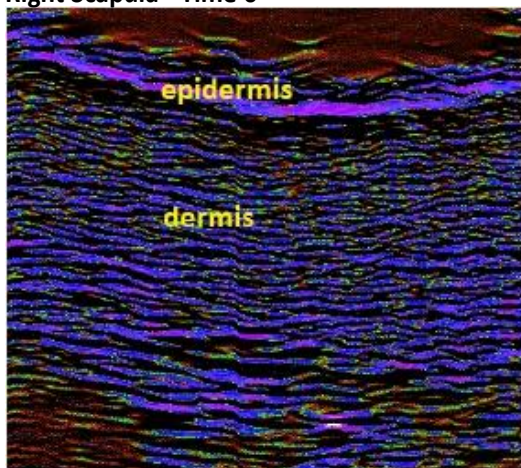
Left Scapula - Time 0



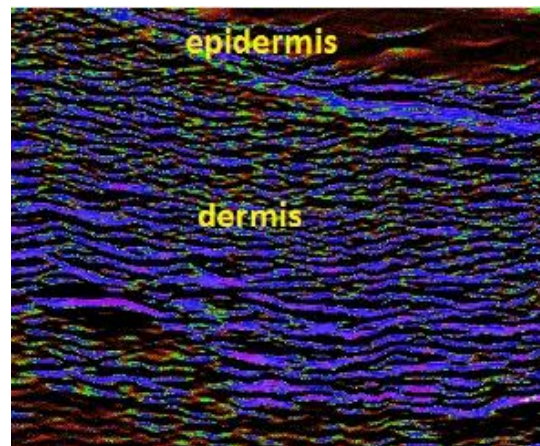
Left Scapula – 4 Weeks



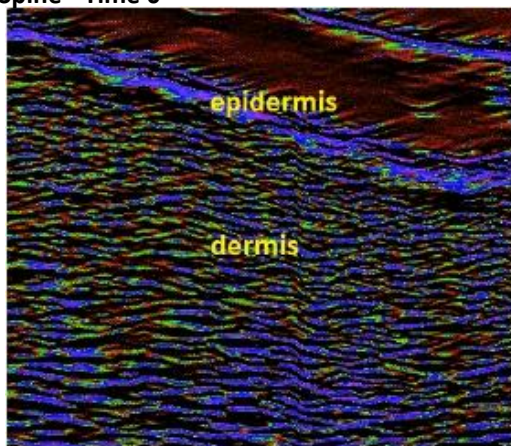
Right Scapula - Time 0



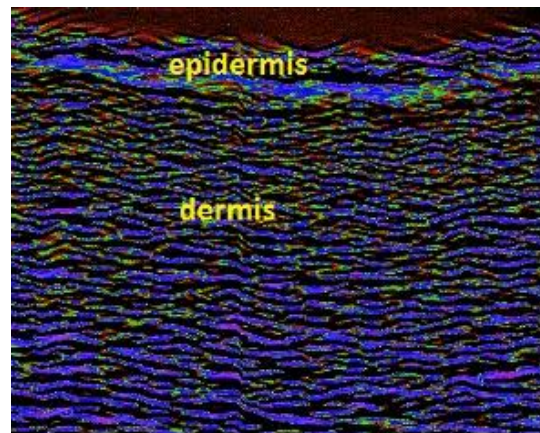
Right Scapula – 4 Weeks



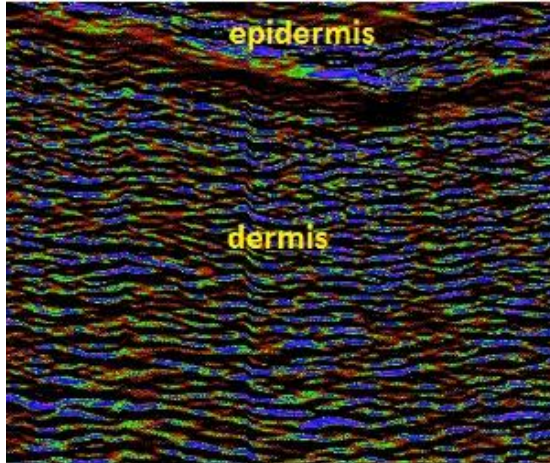
Spine - Time 0




Spine – 4 Weeks



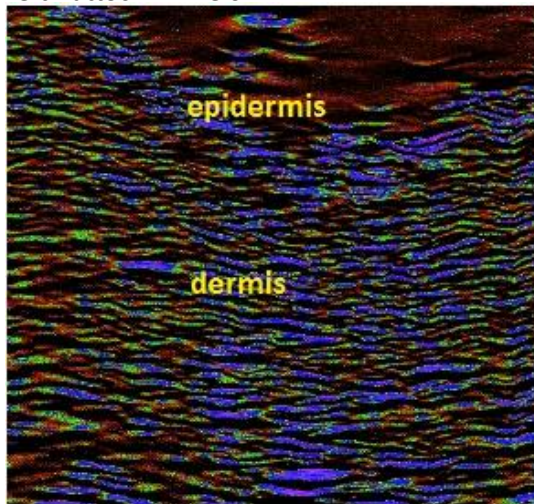
Sacrum - Time 0



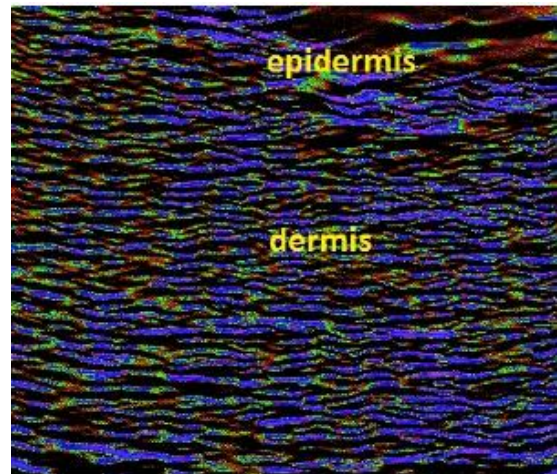
Sacrum - 4 Weeks



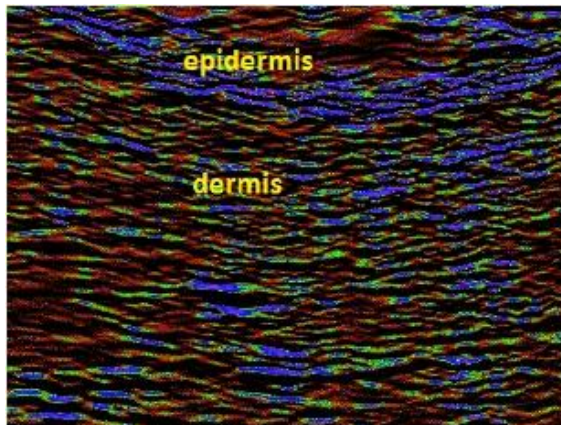
Left Buttock - Time 0



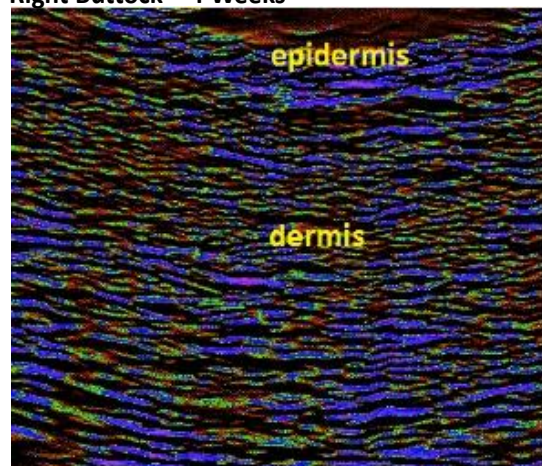
Left Buttock - 4 Weeks



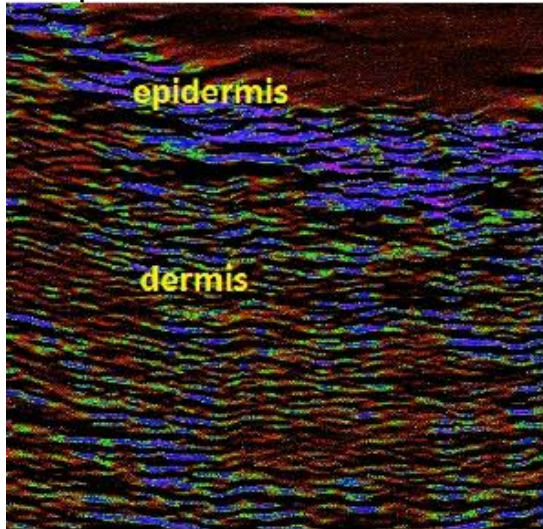
Right Buttock - Time 0



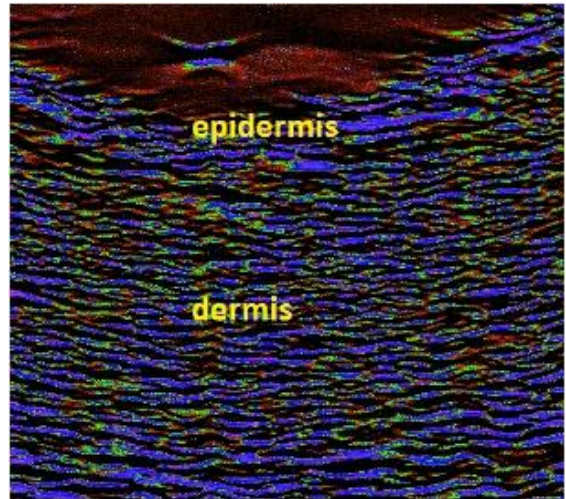
Right Buttock - 4 Weeks



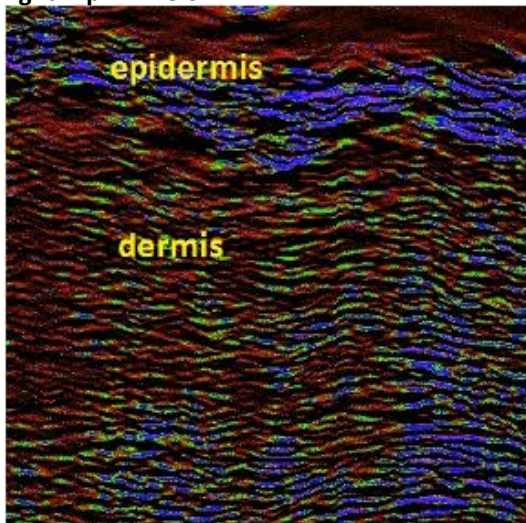
Left Hip - Time 0



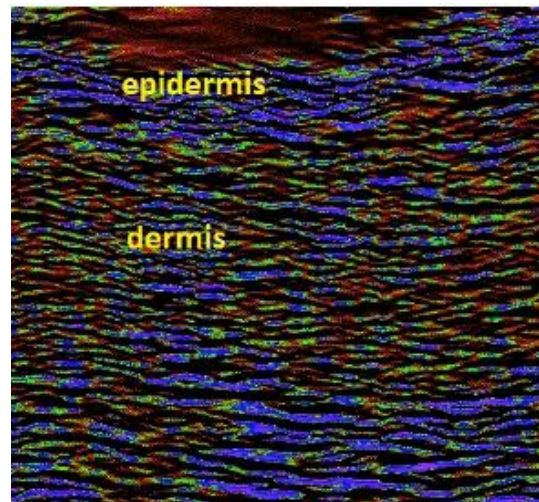
Left Hip - 4 Weeks



Right Hip - Time 0

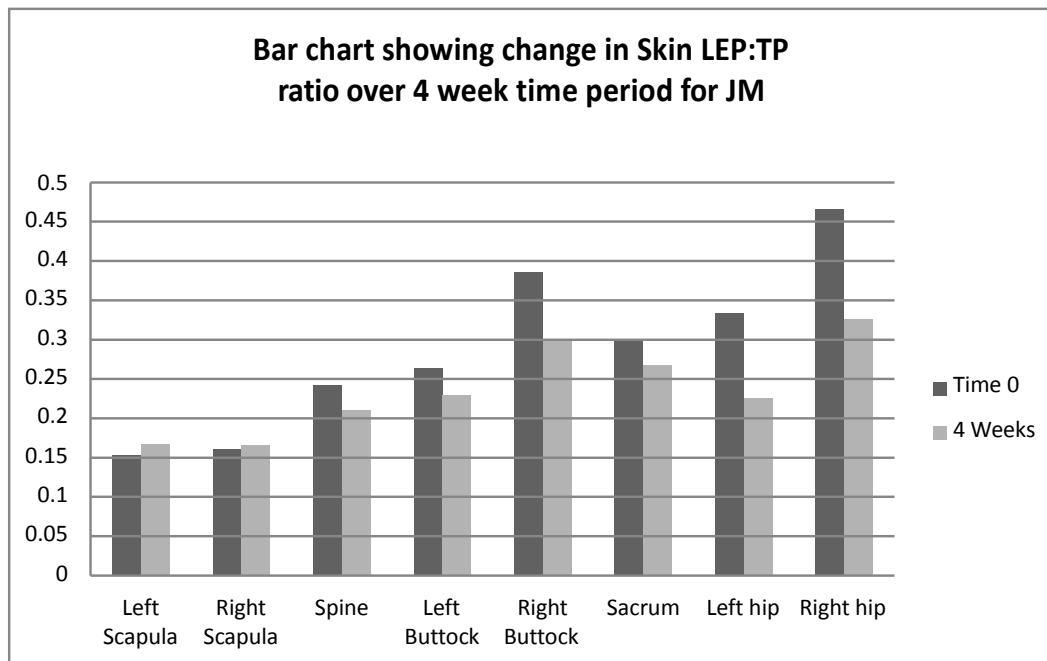


Right Hip - 4 Weeks



The scans shows that in a number of sites the levels of oedema have decreased over time. Analysis of all the scans in this subject are shown in figure 15.

Figure 15 Graph of LEP: TP ratio for JM Skin Analysis



The results show that there changes to be seen in the oedema levels in the skin of this subject when comparing time 0 with 4 weeks. The scapulae show no significant change. Small decreases in oedema are seen in the spine, left buttock and sacrum. More significant changes are seen in the right buttock, and both hips.

Conclusion

The results show that there were varying degrees of effect seen on the subjects with a few areas showing an increase in oedema, some showing no significant change in oedema, however, most areas showed a decrease in oedema. Overall, the results show that the subjects had a positive result by being on the Treat-Eezi bed pad.

The left sacral pressure ulcer data in subject BG showed that the Treat-Eezi bed pad had provided enough pressure relief to enable the wound to heal.

References

1. Young SR, Ballard K. Wound Assessment: Diagnostic and assessment applications – Part 2.. In: Electrotherapy-Evidence based practice 2001. Pp308-312. Churchill-Livingstone (London).
2. Chen L, Dyson M, Rymer J, et.al. The use of high frequency diagnostic ultrasound to investigate the effect of HRT on skin thickness. Skin Research And Technology 2001; 7(2): 95-7
3. Mirpuri N, Young SR. The use of diagnostic ultrasound to assess the skin changes that occur during normal and hypertensive pregnancies. Skin Research and Technology 2001; 7:63-69.
4. Kerr A, Young S, Hampton S. Has packing sinus wounds become a ritualistic practice? British Journal of Nursing 2006; 15(19): S27-S30.
5. Quintavalle P, Lyder CH, Mertz PJ, et.al. Use of high-resolution, high frequency diagnostic ultrasound to investigate the pathogenesis of pressure ulcer development. Adv. Skin & Wound Care 2006; 19(9):498-505.
6. Young S, Bolton PA, Downie J. Use of high-frequency ultrasound in the assessment of injectable dermal fillers. Skin Research and Technology 2008;14: 1-4.
7. Gniadecka M. Localization of dermal edema in lipodermatosclerosis, lymphedema, and cardiac insufficiency: high-frequency ultrasound examination of intradermal echogenicity. J Am Acad Dermatol. 1996; 35:37-41.
8. Gniadecka M, Quistorff B. Assessment of dermal water by high-frequency ultrasound: comparative studies with nuclear magnetic resonance. Br J Dermatol. 1996; 135:218-224